

27 YEARS OF LASER TREATMENT: A PERSONAL PERSPECTIVE

Toshio Ohshiro, M.D.

*Japan Medical Laser Laboratory, Shinanomachi,
and the Ohshiro Clinics, Shinanomachi and Ginza, Tokyo, Japan*

The author presents a twenty-seven year retrospective overview of his work in laser surgery and, more specifically, laser therapy, during which over 45,000 patients have been treated at the author's clinics as of June 2001. The author traces his laser roots, starting in 1974 with his visit to the laboratory and clinic of the late Professor Leon Goldman at the University of Cincinnati to study the evolution of cutaneous laser treatment. Upon returning to Japan, the author developed and used the new laser technology first in Shizuoka and then in Tokyo. He used the laser to remove congenital and acquired pigmented nevi, hemangioma and other cutaneous defects, and by 1978 had treated over 3,000 patients. In the course of these treatments he noted some interesting phenomena associated specifically with laser treatment compared with conventional methodology, such as the ability to treat side effects caused by some of the conventional methods. He also noted that treatment of target lesions with laser often concomitantly treated unassociated painful symptoms such as postherpetic neuralgia, consequently in 1979 the author specifically targeted pain applications using existing and newly developed laser systems. These included the defocused beam of the Nd:YAG, the HeNe laser, and a series of diode lasers developed both at the Japan Medical Laser Laboratory and in conjunction with Matsushita Electric Company. The International Society for Laser Surgery and Medicine (ISLSM) held its fourth meeting in Tokyo in 1981, at which the first commercially-available battery-powered laser therapy system was unveiled. Since then many other systems have been developed and experimentally evaluated. In 1988, the author was one of the founding members and the first President of the International Laser Therapy Association, and was the founding Editor-in-Chief of the journal, *Laser Therapy*, first published by John Wiley and Sons of Chichester, UK. To date, using laser therapy alone, over 9,000 patients have been treated at the author's clinics, and a further 29,000 have been treated with laser therapy in combination with laser surgery, as part of the author's total treatment concept (TTC). Case reports are presented to illustrate the author's concepts of low reactive level laser therapy (LLLT), high reactive level laser treatment (HLLT), and his latest concept of medium reactive level laser treatment (MLLT).

Key words: LLLT; photobioactivation, simultaneous LLLT, nevi, Total Treatment Concept

Introduction

In order to understand how I became interested in laser therapy, I would like to begin with a summary of my medical school history. In 1965, having chosen plastic surgery as my specialty, I was working at Keio University School of Medicine in the department of Plastic and Reconstructive Surgery under professor Eiji Itoh. My particular interest was in the formation of hypertrophic scars and secondary hyperpigmentation following skin grafting and flap transfer. And Dr Itoh tasked me with studying the formation of these entities to try and improve the clinical result. In 1966, I therefore studied melanogenesis under Dr Seiji Makoto, recognised world wide as an expert on melanin synthesis, at the Tokyo Medical and Dental University. I organized a plastic and reconstructive surgical group at this university, where we examined melanin problems in

scar formation, and also studied dermal melanogenesis. (1) After two years I had to return to clinical practice of plastic surgery, but I had a much better understanding of melanin and its formation, particularly following any major plastic surgical procedure, and especially in the Japanese skin.

Even after returning to the department of plastic surgery, my interest in the skin color problems expanded to include treatment of blood vessel and melanin anomaly groups (BVAG and MAG), which at that time were treated in the department of plastic surgery, orthopedic surgery, dermatology and radiology. To combine the merits of the technology in each department, I decided to develop the color clinic in my department of plastic surgery in Keio University.

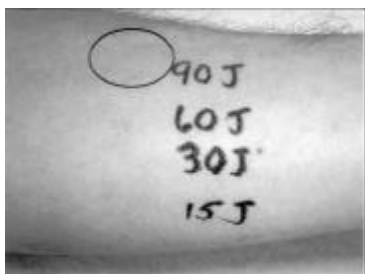

Fig 1:
Test sites on the author's forearm, 24 years after he tested the millisecond pulsed ruby laser on himself at 90 J, 60 J, 30 J and 15 J. Faint scars can still be seen at the 90 J and 60 J impact sites, but no scars at the 30 J and 15 J. These fluences were therefore used on the Japanese skin, with success.

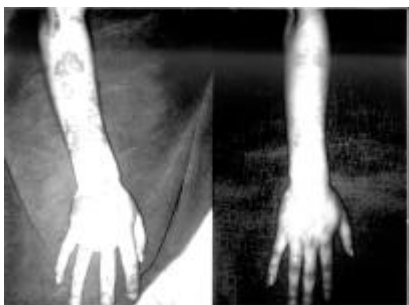


Fig 2:
Hemangioma simplex (HS) on the left forearm of a xx y.o. female(?), before (left) and xx months after ruby laser treatment.

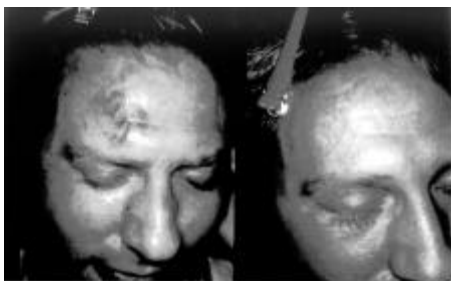

Fig 3:
HS on the right forehead of an xx y.o. non-Japanese patient (left). Because of the different skin characteristics compared with the Japanese skin, this was successfully treated with 90 J, as seen on the right, xx months after treatment.

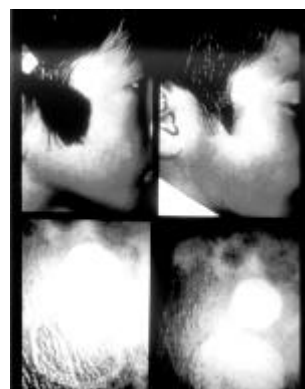


Fig 4:
The ruby laser was efficient in removing the pigment associated with the melanin anomaly group. On the upper left, this xx y.o. had hairy pigmented nevus on the right cheek. Treatment with the ruby laser at xx J not only removed the pigment (upper right), but also removed the coarse hair associated with this condition, leaving finer, lighter hair in its place. On the bottom right, two areas in a hairy pigmented naevus have been treated with the ruby laser. The smaller upper area was test-treated at xx J, spot size of xx cm, one month before, and the result is very good. The larger area is immediately after treatment at yy J, as the aim is to get the best possible result with the minimum dose. The findings on the lower right are one month afterwards, with good selective pigment removal together with the coarse hair. Treatment was therefore carried out at the lower dose.

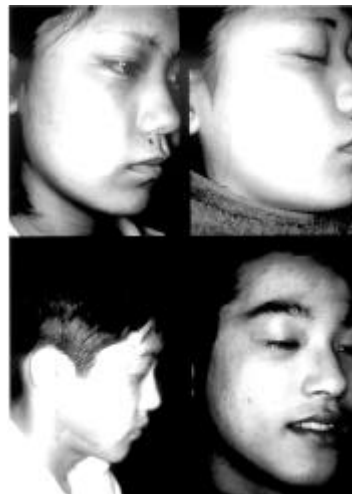

Fig 5:
Two examples of the ruby laser in treatment of nevus spilus, also in the melanin anomaly group, upper left before and upper right xx months after treatment in a xx year old female, and lower left before treatment in a xx year old male, with the result xx months after treatment seen on the right.

Enter the Laser

Despite the above work, the treatment results of BVAG and MAG were still not as good as I would have liked, but I read of revolutionary new work in the USA, specifically at the University of Cincinnati under the late Professor Leon Goldman who was using a new surgical tool, the ruby laser and the argon laser, to treat selected nevi. I therefore went to Cincinnati in 1974, and studied under Professor Goldman for a six month period. During this time I was able to experience, first-hand, the use of the laser in Oriental skin for both hypertrophy and hyperpigmentation, and the results were extremely exciting. We were able to combine the skills of dermatology and plastic surgery with the wonderful new laser technology, and I wanted to purchase the same system as Dr Goldman was using. Unfortunately, the company manufacture had already collapsed. I therefore purchased a commercial industrial system from Korad, the company started by laser pioneer, Dr Theodore Maiman. I encountered many problems in adapting the system to work in the medical field, but my newly-formed Japan Medical Laser Laboratory persisted and finally we solved the problems. As I wanted to treat both BVAG and MAG nevi, I looked for suitable models, finally using the comb from a rooster for the BVAG and the brown areas on guinea pig skin for the MAG models. I finally felt confident to try the system on my own skin, which I did at output energies of 15 J, 30 J, 60 J and 90 J. The latter energy was far too much for the Japanese skin, as a result, I have the scar on my forearm to this day (Figure 1). However, at the lower energies I was confident enough to start using the conventionally pulsed ruby laser system on patients, with great success as seen in Figures 2 and 3 (hemangioma simplex, BVAG) and Figures 4 and 5 (hairy pigmented nevus and nevus spilus, MAG).

During this time I gradually started to form my classification of cutaneous anomalies, which I put classed under the generic term 'nevus' and 'nevi', under three main categories: BVAG, including hemangioma simplex, telangiectasia and so on; MAG, including nevus spilus, hairy pigmented nevus and so on; and others including xanthelasma, verruca vulgaris, hypertrophic scars and so on.

By the end of 1976 I had treated 450 patients at the Shizuoka Red Cross Hospital, which was where I set up a clinic when I returned from the USA, and the numbers were increasing due to the popularity of the treatment. So I returned to Tokyo, moved the Japan Medical Laser Laboratory (JMLL) from Shizuoka and established the Ohshiro Clinic in Kojimachi, area of Tokyo.

Laser Surgery, plus Alpha?

After returning to Tokyo, I soon added argon, CO₂ and

Nd:YAG systems to my laser arsenal, as the ruby was not suitable for all lesions and all areas of the body. By 1979 I had treated around 4,000 patients with laser surgery. During this two years of work with laser surgery, I noticed some extremely interesting facets to the treatments which could only be explained as phenomena associated with the laser as compared with other thermal modalities such as electrocautery. For example, in treating a case of hemangioma simplex (HS) which had been unsuccessfully treated with electrocautery, not only the residual redness of the untreated HS, but also the mini-hypertrophic points left by the electrocautery needle (Figure 6) were removed at the same time. These phenomena meant that the laser was delivering not only a thermal effect, which could remove the redness of HS, but also had an alpha effect, by which the hypertrophic scars could be removed.

Other alpha effects were being reported in the literature. Patients reported that they felt less postsurgical pain with the laser compared with conventional methods, and most importantly for my future interest in laser therapy, patients being treated specifically for nevus were reporting that non-related painful symptoms in the general area were also successfully removed. In treating another case of HS on the sternum of a female patient who was also suffering from severe chronic postherpetic neuralgia (PHN) for which she had been unsuccessfully treated with 300 nerve block sessions, not only was the HS successfully treated, the PHN was resolved simultaneously

The argon laser was used in my zebra method to treat the HS (Figure 7), and after the third session the patient's pain from PHN was gone. I surmised that the argon laser energy was penetrating into the tissue, beyond the area of thermal reaction, at much lower photon densities, and was acting on the hyperexcited intercostal nerves to reduce and finally remove the PHN, which can be considered as one of the alpha effects associated with laser surgery.

From Laser Surgery to Laser Therapy

My attention was therefore diverted into developing and experimenting with nonsurgical laser systems, what I now term low reactive level laser therapy, or LLLT. I used at first the defocused beam of the Nd:YAG, as that wavelength appeared to offer a deep penetration to reach deeper-sited pain entities. Then we discovered the semiconductor laser, the Gallium Arsenide (GaAs) diode laser, and started to develop systems based around this system at the deeper penetrating 830 nm. The Gallium Aluminium Arsenide (Ga-Al-As) diode then became available which offered better power output at 830 nm with less cooling problems than the GaAs system. The helium neon (HeNe) laser was also available, at the visible red 632

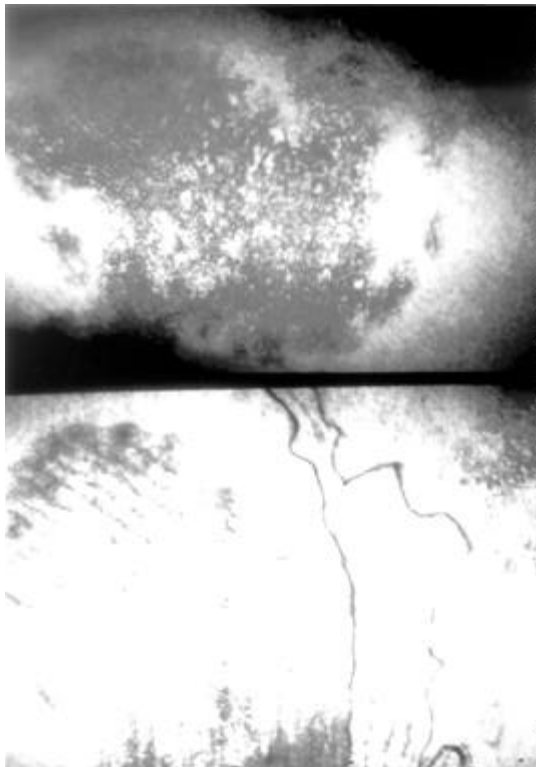
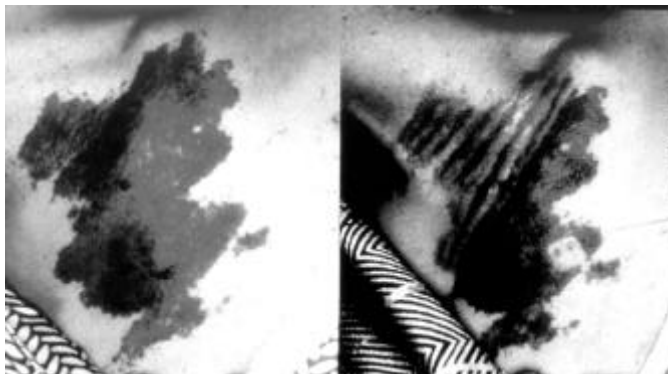

Fig 6:

An example of the alpha-effect seen with the laser, compared with conventional methodology. On the left can be seen a case of HS in a xx y.o. female. She had been treated elsewhere with needle electrocautery, but there is residual untreated HS together with micro-points of hypertrophy left by the electrocautery needle. Electrocautery also relies on a thermal effect to achieve results, but they were not good. On the right, following treatment with the argon laser in the author's 'zebra' method, not only has the remaining HS been removed in the treated areas, but the hypertrophy



has also been treated.

Fig 7:

The genesis of the author's interest in pain attenuation with laser therapy. (Upper) An HS on the sternum of a xx y.o.

female, who was suffering from chronic postherpetic neuralgia (PHN), despite over 300 nerve block sessions. The author applied the argon laser in the zebra method, and after the first two sessions not only was the HS removed, but the patient also noted the disappearance of her PHN.



Fig 8:

Founding members of the International Laser Therapy Association (ILTA) after the inaugural session held at the Hilton Hotel, London, in July 1988, from the left, Peter Hassan (Indonesia), Kevin Moore (UK), Adam Mester (Hungary), Kenichiro?? Inomata (Japan), Toshio Ohshiro (Japan), John Carruth (UK), Mario Trelles (Spain), Robert Scott (USA) R Glen Calderhead (Japan), Naru Hira (UK) Mary Dyson (UK), Ming-Chien Kao (Taiwan).

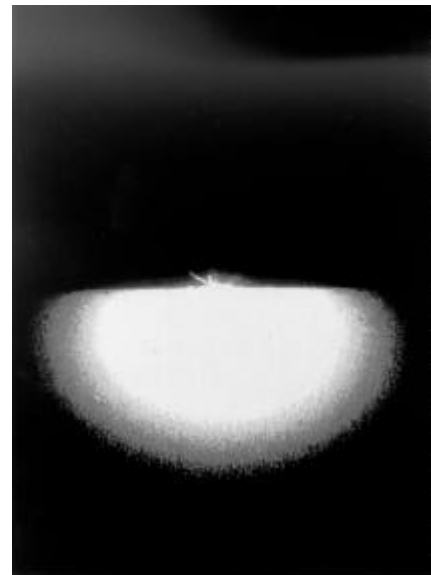

Fig 9:

Evolution of the author's 'laser apple' concept, as seen by the typical patten of laser-irradiated material.

nm, and my group and I used that system also. We were looking first of all mainly at pain applications, but we also found some good effects when we used LLLT after surgery, as far as wound healing and control of postsurgical side effects were concerned, in 1980 I started to make a prototype GaAs diode laser, and then began to work in cooperation with Matsushita Electric Company. Subsequently, in 1981 we announced the first battery-powered GaAlAs diode laser and demonstrated it at the 4th congress of the International Society for Lasers in Surgery and Medicine (ISLSM), held that year in Tokyo. The late Professor Endré Mester was present at that meeting, and we had many deep discussions regarding laser therapy. If Leon Goldman was the Godfather of laser surgery, then Endré Mester was the Godfather of laser therapy. He influenced me greatly, giving me the inspiration to continue in my LLLT efforts both clinically and experimentally.

In 1988, I published, with John Wiley and Sons of Chichester, UK, the first book dedicated to laser therapy,[2] and in the same year the same publishers bravely announced the publication of the international journal 'Laser Therapy', dedicated to the concepts of laser therapy and photobioactivation, and of which I had the honor to be the founding Editor-in-Chief. In the same year, together with some interested and preeminent colleagues I founded the International Laser Therapy Association (ILTA) in London (Figure 8), and the Association held the first ILTA congress in Okinawa in 1990, with me as President.

As for patients, from 1974 to 2001 my colleagues and I have treated over 38,000 patients using LLLT alone, mostly pain entities, both acute and chronic. However, using laser surgery I have treated over 36,000 patients, and out of these some 29,000 have received laser therapy as prophylaxis against scarring and hyperpigmentation, and to accelerate wound healing. During this time I have refined my ideas on LLLT, its mechanisms and pathways. In the remainder of this article, I would like to share these with the readers of Laser Therapy. As this is a review paper, I apologize in advance if I do not go into too much depth or cover every available topic. I hope the readers will understand.

Laser Surgery and Laser Therapy

From my early experience with the simultaneous effects of laser therapy associated with laser surgery, it was clear that there was a big difference in the effects of laser energy depending on the power density, or photon density of the incident beam on tissue. Even in the early days I had evolved my 'laser apple' idea of the incident laser beam (Figure 9) [3], and this led naturally to the evolution of the

photodestructive and photoactivative sides of the laser beam, as seen in Figure 10. This is a schematic representing an incident surgical laser beam on tissue [4]. The first few layers of carbonization, Vaporization, hemocoagulation and protein coagulation are all frankly photodestructive, with the temperatures attained either removing tissue, with or without carbonization, or 'cooking' the connective tissue into an amorphous intensely basophilic mass. The photoreactions are temperature specific, but the range of temperatures is specific depending on the laser used and the type of tissue being treated. In general, Vaporization occurs from around 98°C upwards. Tissue carbonization and hemocoagulation occur from approximately 68 °C upwards, with protein degradation seen from about 48°C upwards. Protein denaturation can occur from temperatures as low as 40°C upwards, and at temperatures below 40° the target cells are activated, either medium thermal photoactivation or pure photobioactivation associated with a little or no rise in tissue temperature.

Thus, I originally identified two areas of photoreaction: photodestruction, associated with laser surgery, which I classified as high reactive level laser treatment (HLLT); and photobioactivation, associated with laser therapy, which I classified as low reactive level laser therapy (LLLT). I have now revised my opinion to include a third area which exists between these two clear-cut regions. Figure 11 further refines the concept by looking at the survival threshold of the cell. If the cell is damaged to levels above the survival threshold, it will die. Hence my terminology of high reactive level laser treatment, as the level of reaction in the cell is higher than the survival threshold. On the other hand, when the cell is purely activated, in the photobioactivation zones, it is encouraged to become much more active than normal, either performing its normal function faster and more efficiently, or releasing a number of factors and other products which transfer information or energy to surrounding unirradiated cells. This explains my terminology of low reactive level laser therapy (LLLT) because the level of reaction in the cell is much lower than the survival threshold.

From Figure 11, however, it can be seen that a 'grey area' occurs from the pure photobioactivation zones up to the survival threshold. In the protein degradation level, the cell is damaged. The damage to the cell is partly lower than its survival threshold, then the cell will most probably survive. at least for some period of time. However, in portions of the protein denaturation level, the slight to moderate damage acts as a stimulus to the surrounding cells, encouraging it to greater levels of energy than normal, or it may cause the cell to enter apoptosis during which it secretes products which help to stimulate the surrounding

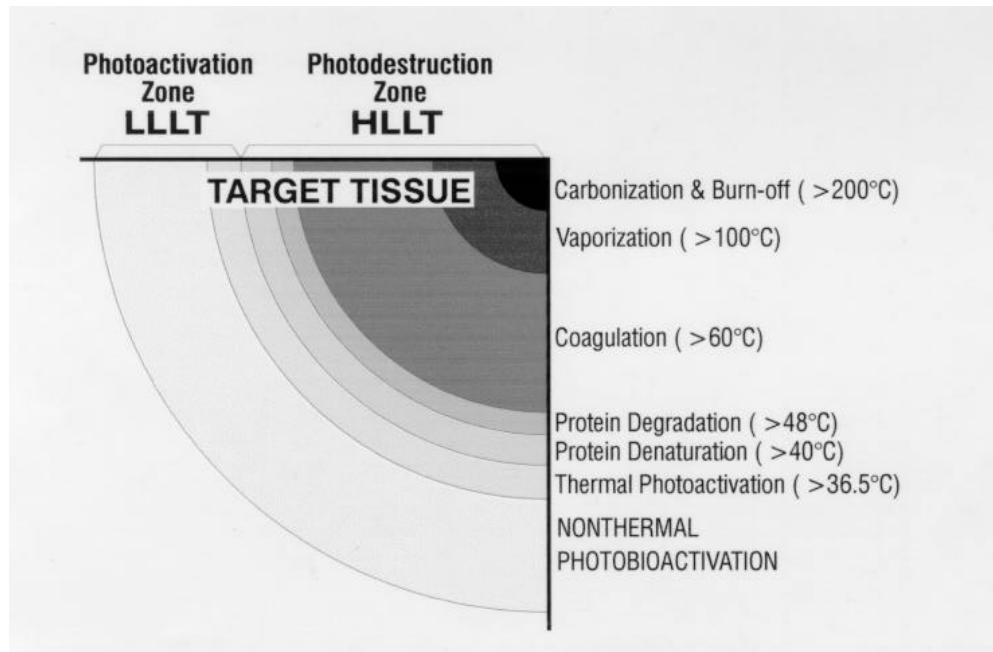


Fig 10:
Schematic of a typical surgical laser impact on tissue, with zones of thermally-dependent reactions from extreme heat at the impact point to little or no heat effect in the deeper layers. In this older concept, the author divided the damage into photodestructive (laser surgery or HLLT) and photoactivative (LLLT) zones.

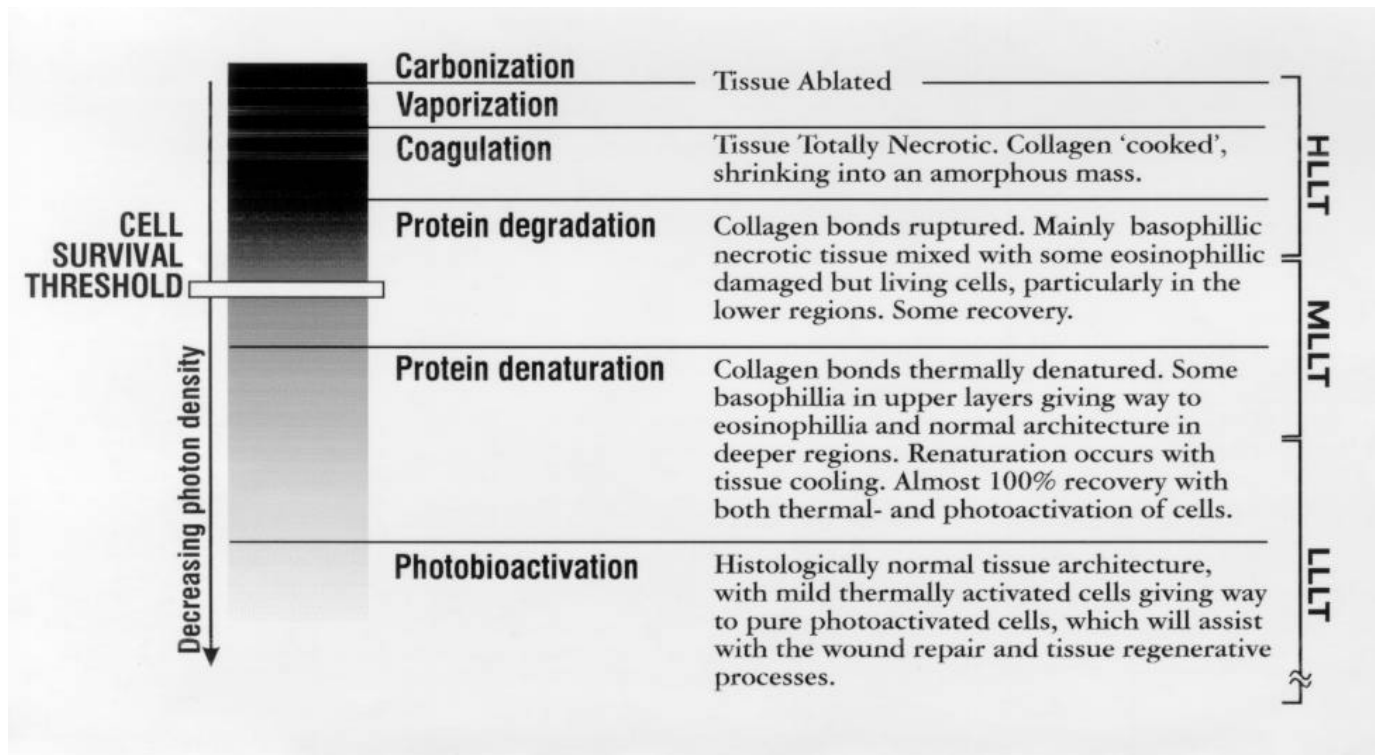


Fig 11:
The same concept refined by taking the cell survival threshold as the criterion for treatment effect. From this it can be seen that there is a 'grey area' between photodestruction and photoactivation, where cells may be damaged, but the damage is below their survival threshold and they will survive. This damage is in itself a stimulus however, and so the author evolved his terminology of medium reactive level laser treatment (MLLT), used to explain the tissue reactions in laser welding and nonablative photorejuvenation.

cells to become more active. This corresponds in microscopic histological specimens to the region of mild protein degradation and protein denaturation which is seen as an area of transition from basophilia to eosinophilia, beyond which completely normal tissue architecture appears. I have therefore since added another term to my previous two of HLLT and LLLT, namely medium reactive level laser treatment, or MLLT. In this zone, laser welding or laser shrinkage can be achieved, so this is an important zone when we consider the extremely popular cosmetic treatments using laser, for example, for hair removal and nonablative photorejuvenation. In neither of these treatments is the epidermis visibly damaged, yet a reaction occurs in the controllably damaged dermal tissue which produces the desired clinical cosmetic endpoint. This is not laser surgery, nor is it laser therapy, although it owes much of the desired effect to the latter. Hence I felt that the term MLLT was required to bridge the gap between HLLT and LLLT.

History of Clinical Laser Application

My history of clinical laser application can be described schematically as in Figure 12. From plastic surgery I expanded my research and applications to include dermatology, and then as described above diversified into the areas of HLLT and LLLT. I will concentrate on the LLLT applications, as this is not an appropriate forum for laser surgery.

Pain Attenuation

The first main applications of laser therapy were in the area of pain attenuation, and the pain clinic remains a major part of my LLLT indications. Typically in the pain clinic we treat acute and chronic pain entities of the musculoskeletal system including postherpetic neuralgia (PHN) [5] spinal pain entities including lumbar pain [6], a variety of headaches [7,8], whiplash syndrome [9], periarthroses of the major joints [10], frozen shoulder [11] and so on.

At the 1981 ISLSM meeting in Tokyo, Laser Tokyo '81, my JMLL group presented a paper comparing the use of the defocused Nd:YAG with the first 15 mW GaAlAs portable 830 nm diode laser system for pain attenuation, [12]. Even at that early stage, our results with the comparatively low-powered diode system were extremely promising. As I developed more powerful systems, I designed a series of trials to elicit the best combination of power and available wavelengths for pain attenuation. From these I discovered that 830 nm produced the most effective overall attenuation of chronic and acute pain, and that the gallium aluminium arsenide diode was most efficient in generating this wavelength. I further found that the output power of 60 mW with the continuous wave (cw) GaAlAs system I had developed, the OhLase-3D1, was significantly more effective

than 50 mW and below, but greater output powers did not produce concomitantly better results, thus this system was designed to optimize these parameters and has had great success, remaining till today the main system I use in my pain clinics. The system delivers an incident power density of approximately 3 W/cm², and I usually deliver between 15 J/cm² and 50 J/cm² per point in the contact pressure method.

One of my earliest patients was a professional baseball pitcher with extreme acute pain of his arms and intercostal regions diagnosed as muscle strain after overtraining. The thermographic findings pre and post treatment with 60 mW 830 nm cw diode laser therapy are seen in Figure 13. The areas of elevated temperature associated with underlying inflammation are clearly seen in the upper figure, and are removed in the lower. Unable to pitch when he presented at my clinic, he went on the three days later to pitch a shutout after one intensive treatment session. In 1987 I took my OhLase-3D1 system to Dr Kevin Moore of Oldham, U.K., no stranger to readers of Laser Therapy. Dr Moore had assembled 26 problematic patients from his extensive pain clinic with a variety of acute and chronic entities. Figures 14 and 15 show two representative examples of an acute sprain and chronic frozen shoulder, respectively, pre and post treatment, taken from a video footage shot by Royal Oldham technicians. We also successfully treated a case of chronic postherpetic neuralgia, which prompted Dr Moore to design his well known double blind cross-over study on PHN,(5) which was subsequently replicated with approximately the same degree of significant success here in Japan, (13) and in Canada.(14)

In addition to acute pain, I also found the system extremely good for chronic pain. Figure 16 shows the thermographic findings in a young lady with chronic abdominal pain, areas of pain and numbness in her upper extremities, painfully cold hands, and irregular menstruation. Contrary to the findings with acute pain, the areas of elevated temperature are replaced with areas of decreased temperature indicative of circulatory problems caused by the chronic nature of the pain. Acute pain, if untreated or treated incorrectly, gradually results in fibrotic nodule formation which compresses nerves and blood vessels resulting in result point seen in the upper part of Figure 16. outcome. The painful sites are now no longer under direct control of the nervous systems, which in turn are the responsibility of the brain. (15) My theory postulates that LLLT removes the fibrosis and restarts the stagnant lymphatic flow, thereby restoring local control to the mother brain. In the lower portion of the figure the dramatic rise in temperature over the entire head, torso and upper extremities is indicative of the whole body warming effect seen with laser therapy,

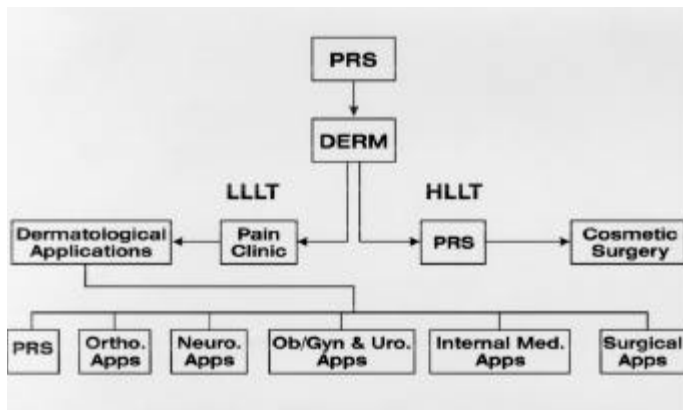


Fig 12:
Schematic of the author's history of clinical laser indications.

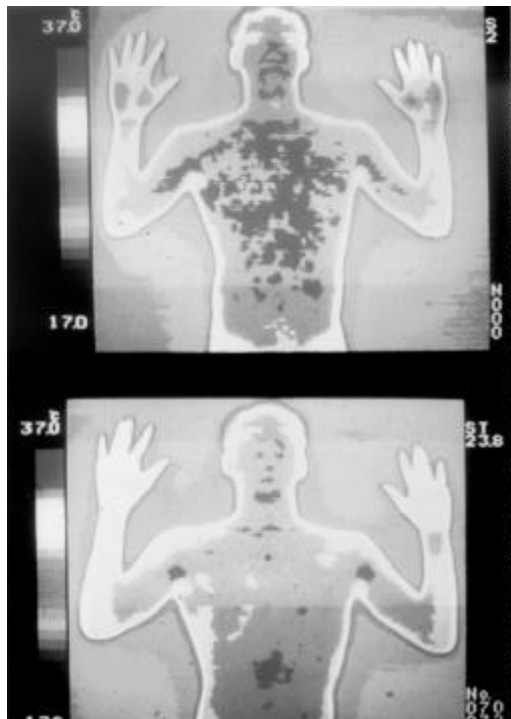

Fig 13:
Thermographic findings of acute strain of the intercostal muscles following overtraining in a xx year old baseball player before (upper) and after (lower) GaAlAs diode laser therapy. The areas of high temperature indicative of inflammatory response are removed in the lower part of the figure.

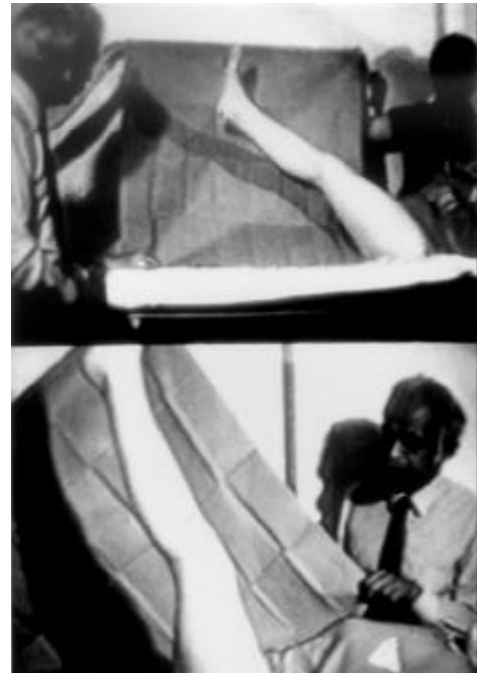

Fig 14:
Acute sprain of the left leg in a xx y.o. female following a riding accident showing the ROM before (left) and (right) after GaAlAs diode laser therapy. These pictures were taken at Kevin Moore's pain clinic in Oldham, UK in September 1987.



Fig 15:
Chronic frozen shoulder in a xx y.o. male, also taken at Dr Moore's clinic. ROM is shown before (upper) and (lower) after GaAlAs diode laser therapy.

and documented in excellent articles by my colleague Dr Asagai, who treated adult cerebral palsy patients with the OhLase-3D1 as part of a total functional training program with good results.(16) This has led to the extension of my theory of laser therapy-mediated reversal of the sympathetic-dominant highly tense state as seen in Figure 16, pre-treatment, and to a parasympathetic-dominant relaxed state, as seen in the post-LLLT findings.

Dermatological Applications

Following early success in the pain clinic, I moved on to assess the use of LLLT in dermatology-related diseases and conditions, including hypertrophic scars and keloids,(17) revitalization of failing skin grafts and flaps,(18,19) hyper- and hypopigmentation, vitiligo,(20) atopic dermatitis, atrophic skin, psoriasis vulgaris, strawberry hemangioma in infants,(21) and so on. Figure 17 shows the progress over two years of the use of LLLT alone (830 nm, 60 mW, cm, 30 J/cm²) in treatment of a hypertrophic keloid following an abdominal operation in a female. Figures 18 and 19 show the effective use of LLLT in the treatment of systemic vitiligo. Figures 20 and 21 show laser therapy used to effectively by control and treat atopic dermatitis, an increasing problem here in Japan. Figure 22 shows the use of laser therapy in the combination of iatrogenic vitiligo and border hyperpigmentation caused by overtreatment of a systemic vitiligo with PUVA (psoralen and UVA) therapy. LLLT reduced the hyperpigmented border and restored some normal pigment to the hypo- and depigmented zone, with a very cosmetically-acceptable result. Strawberry hemangiomas (SHs) are a major problem for infants and their parents. The conventional wisdom adopts a 'wait and see' attitude, as a large majority of these troubling lesions spontaneously resolve. However some may involve the eyes, threatening the sight of the patient. Others can involve and restrict the nasal airway. Many are subject to frequent bleeding, either spontaneous or through self-excoriation. In these cases, treatment is certainly required. However, we treat all SHs with LLLT, as the involution phase is reached much earlier, and very often with much better results. Figure 23 shows a representative example of the course of successful involution of large SHs on the arm of young girl.

Plastic Surgical Applications

After the success of laser therapy in both the pain clinic and dermatology, I moved on more or less in parallel to a number of other indications. In plastic surgery I looked at a number of indications, including flap and graft problems and their solution; wound healing acceleration; control of severe ulcer formation; tissue welding and so on. Failing grafts and flaps due to vascular compromise are a major problem for the plastic surgeon and dermatologist.

Together with my colleague Dr Junichiro Kubota I started in the early and mid eighties-a series of rat experiments to assess the use of LLLT in promoting flap survival. (22) The findings proved that there was a laser-specific reaction in the laser therapy treated flaps compared with the untreated control and non-laser but same wavelength light irradiated animals. We found better earlier perfusion (Figure 24), better angiogenesis (Figure 25) and better flap survival (Figure 26) in the laser-treated group compared with the other two, but no difference between the untreated and non-laser treated group. Subsequent studies using laser speckle flowmetry have corroborated the earlier studies, and clinical experience has borne out the experimental data.(23,24)

Figure 27, courtesy of Dr Yu Maruyama, shows LLLT (830 nm, cw, 60 mW, contact method) saving a necrotic flap following free flap formation to repair a major defect left after a traffic accident. The progress of the revascularization of the flap can be seen, together with the final result. Hematoma formation is a major problem in skin grafting, as the hematoma prevents the take between the graft and the wound bed. Dr Kioizumi presented a series of clinical findings of LLLT in the restoration of failing skin grafts of which Figure 28 is a representative example.(18) Concomitantly he showed in experimental studies(25) that LLLT had a number of important reactions on hematoma. The levels of prostaglandin E₁₂ were significantly increased, which is an antiagregant for platelets. In addition the increased blood and lymphatic flow in the irradiated area significantly increased the presence of nutrients, scavenger cells and neovascularization, while at the same time increasing the levels of lysing agents for the fibrin mesh holding the hematoma together.

The earlier work of Dr Lisa Schindl on LLLT and Buerger's disease, thromboangiitis obliterans,(27) prompted us to start our own work. Figure 29 shows the typical ulcerous destruction of the big toe in an early stage Buerger's patient before and 15 months after 830 nm diode laser therapy. The patient was also in extreme pain, another feature of this disease, and the patient's pain was also totally removed. Figure 30 shows the pre- and post-LLLT plain angiographic findings in the same patient in the affected limb at the femoral artery level. The neoangiogenesis budding and branching is clearly demonstrated, weeks after the first LLLT session, which is the basis of the long-term effectiveness of LLLT in this otherwise incurable progressive and possibly fatal disease. Dr Schindl's follow-up periods are currently well over nine years for her early patients, with no recurrence. Despite our best efforts and instructions, patients will occasionally not practice the correct wound care proce-

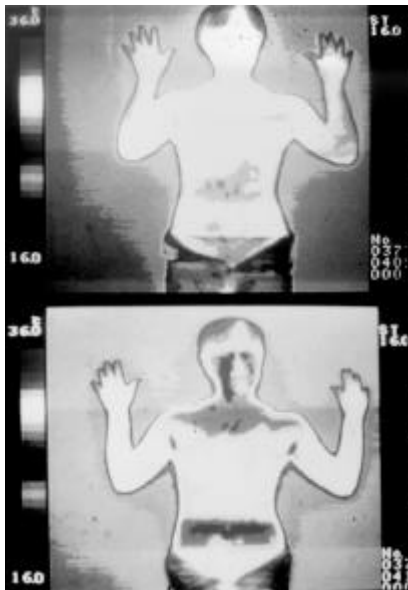

Fig 16:

Thermographic findings in chronic pain before (upper) and (lower) immediately after diode laser therapy in a xx y.o. female with abdominal pains, pains in the upper and lower extremities, migraines and menstruation abnormalities. Unlike acute pain, the thermography shows extensive areas of extremely low temperature indicative of poor circulation caused by areas of fibrotic nodules, in turn causing lympho-concentration. Laser therapy restores normal communication between the treated areas and the 'mother computer', also restoring circulation as seen in the lower figure.

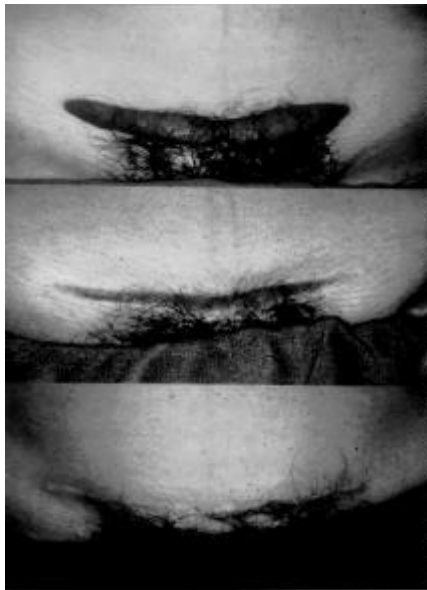

Fig 17:

Hypertrophic scar following a hysterectomy treated with diode laser therapy. Before (upper), during (middle) and (lower) 19 months after the first LLLT session.

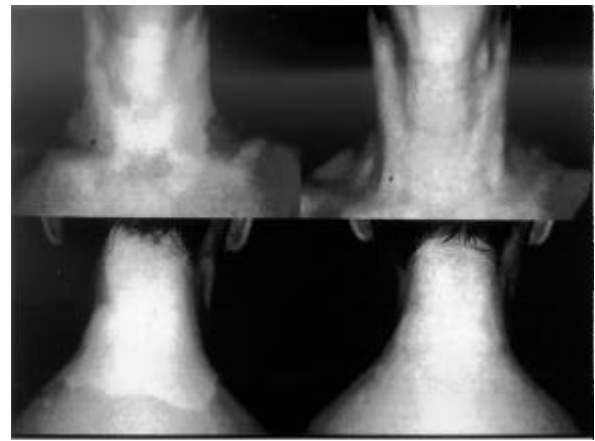


Fig 18:

Laser therapy for systemic vitiligo on the neck of a xx y.o. female before (left upper and lower) and three years after GaAlAs diode laser LLLT (upper and lower right)

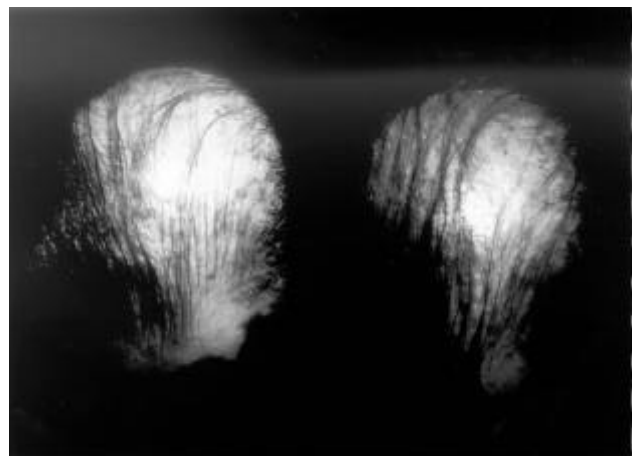


Fig 19:

Another example of LLLT for systemic vitiligo on the scalp of a xx y.o. male, before (left) and one month after (right) diode laser LLLT.

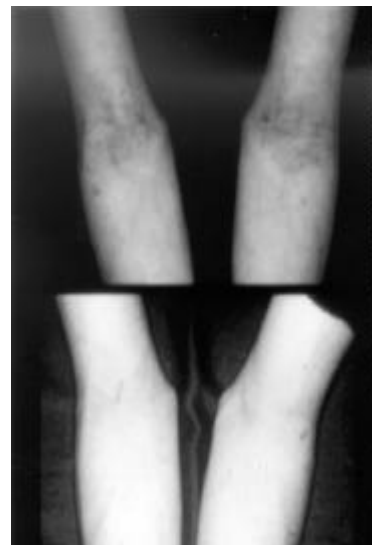


Fig 20:

LLLT in immune system-related conditions. Atopic dermatitis on the bilateral arms of a xx y.o. female before (upper) and (lower) xx weeks after LLLT.

ture following surgical treatment. With conventional or lasers, therapy. Unpleasant sequelae occur, such as ulceration, as seen in the patient in Figure 31, taken from my earlier experience. I first used the defocused Nd:YAG on the lesions, with minor success, but with the appearance of the 830 nm diode laser, the improvement was rapid and complete. Other authors have also published a series on the use of LLLT for control and healing of postoperative ulcerations.(19)

Orthopaedic Applications

LLLT is ideally suited for orthopaedic indications, many of which cross-over from the pain clinic, including sprains and strains, tendinitis, contusions, bone fusion, slow-union fractures, whiplash syndromes, frozen shoulders, rotator cuff syndrome, rheumatoid disorders, and so on. The experimental work in this field has been very supportive of the excellent clinical findings. Bone fusion happens faster with LLLT.(27) Superior osseointegration, whereby biocompatible implants are integrated into and with growing bone tissue, has been demonstrated experimentally, and clinically.(28) Delayed union fractures have been cured with LLLT,(29) even in the presence of bone disease such as osteomyelitis (Figure 32).(30) Lumbar disc herniation has been reversed, with strength and elasticity returned to the weakened annulus with better retention of the nucleus pulposus (Figure 33, with MRI imaging).(31) Arthroses, in particular rheumatoid arthritis, have been successfully treated with LLLT, and experimental data back up the clinical findings with reduction of the RA signs in blood chemistry and smoothing of pain-related microvilli on the joint cartilages.(32,33) Figures 13 and 14 above are good examples of acute and chronic cases successfully and speedily treated with LLLT.

Neurosurgical Applications

A field where laser therapy is finding more and more applications is neurosurgery, including neuralgia, in particular occipital (major and minor) and trigeminal neuralgia; facial (Bell's) palsy; migraine headaches; and repair of spinal and other nerve defects with the remyelination of demyelinated fibres.(34,35) Figures 34 and 35 show the pre- and post LLLT findings in a male patient with left-sided facial palsy.

Ob/Gyn and Urological Applications.

This is another fast-expanding field where LLLT is having many successes, including female infertility, indolent delivery, menstruation pain, male infertility, benign prostatic hyperplasia, and so on. Figure 36 shows a selection of babies borne to supposedly 'infertile' women after treatment in a study with a 60 mW 830 nm diode laser. The study spanned from 1996 to 2000, and 74 patients were enrolled in the study. The average age was 39.3, and the

mean period of infertility was 9 years. Fertilization procedures, such as in vitro fertilization and artificial insemination, had been attempted on average 15.3 times, and all participants had been classed as 'poor responders' with extremely severe infertility. The average number of laser therapy sessions was 21.3, with an average time per session of 12 min 23 sec. Laser therapy was carried out with the OhLase-3D1 GaAlAs diode laser. During the period of the study, there were 15 pregnancies, including five miscarriages. In the ten who successfully came to term, two were delivered of twins, giving a total of 12 healthy laser babies.

An earlier study from the Department of Obstetrics by Dr Uchino at the Kitazato hospital on the use of LLLT in difficult and indolent births showed a statistically significant decrease in labour time following LLLT, even compared with normal births without LLLT, as summarized in Figure 37.(36) LLLT has been reported as successful in prostate.(37) More data are expected as applications increase and experimental studies are designed to elicit the pathways and mechanisms of LLLT in these areas.

Internal Medicine Applications

LLLT has been and is being increasingly applied in internal medicine, for such indications as normalization of hyper- and hypotension, control of, diabetes mellitus, Buerger's disease (as discussed above) infant diarrhoea and so on. Hypertension control made television news in 1990, during the first congress of the International Laser Therapy Association in Okinawa. One of the keynote guests was Nobel laureate Arthur Schawlow. During the meeting he complained of severe hypertension headaches, and agreed to being treated on camera. The director of US Kadena Air Force Base hospital was on hand objectively measure Dr Schawlow's blood pressure, which was 180/140 before treatment 180/140. Immediately after treatment with the OhLase-3D1 (Figure 38), Dr Schawlow's BP was down to 140/100, and 24 hours after the single treatment it was 130/90. In a controlled experiment by Umeda et al., LLLT successfully lowered hypertension by a minimum of 10 mm/hg, both systolic and diastolic readings, in over 80% of 30 WHO-rated hypertensive patients.(38) A control group of normotensive patients showed almost no change in their BP at all following LLLT, except for three who were actually hypotensive whose BPs were elevated towards normal. An early series of trials from China pointed to the efficacy of LLLT in infant diarrhea,(40) and this has been corroborated by ourselves and others.

Surgical Applications

Many of the applications in surgery have already been dealt with, and include wound healing acceleration, circulatory disorders, postoperative pain, oedema, hematoma,

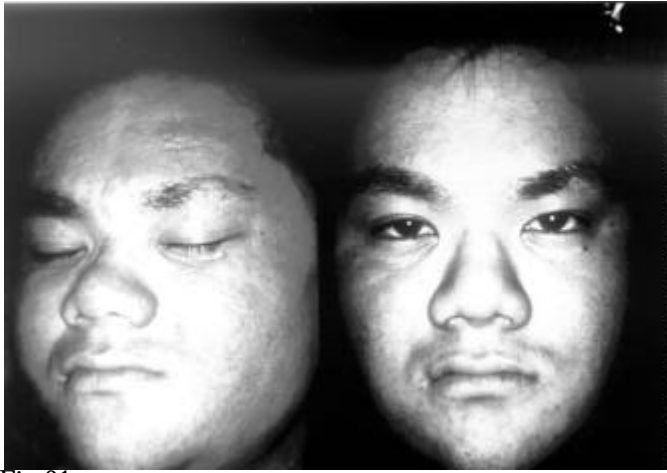

Fig 21:
Atopic dermatitis on the face of a xx y.o. male before (left) and (right) 2 months(?) after LLLT.

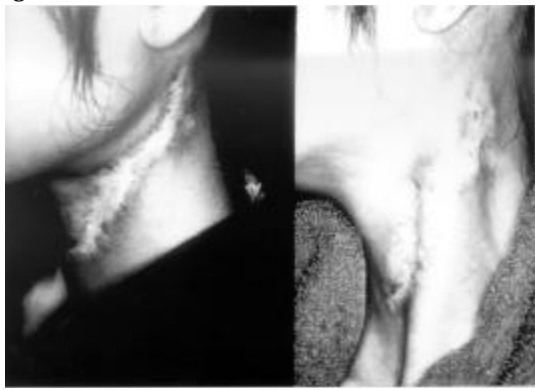

Fig 22:
Iatrogenic vitiligo caused by PUVA treatment of systemic vitiligo complicated with hyperpigmentation of the border of the vitiginous area ina xx y.o. female before (left) and (right) one year after laser therapy with the GaAl As diode laser.



Fig 23:
Strawberry hemangioma on the right arm of an infant before (upper), during (middle) and after (lower) xx months of diode laser therapy. Excellent involution and skin texture with no residual components of the SH remaining.

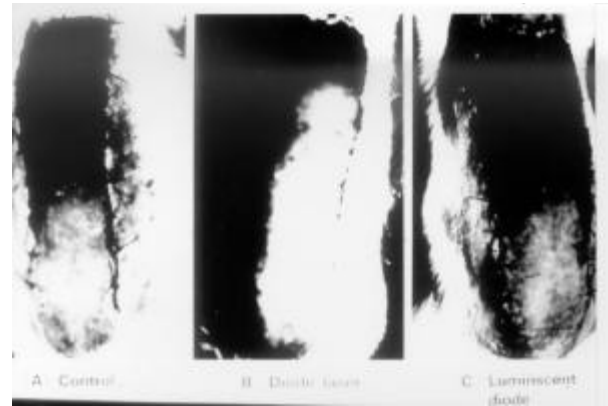


Fig 24:
LLLT in an experiment on flaps in the rat model. Fluorescein angiography shows poor perfusion on the control (left) and LED-irradiated animals (right) with good flap perfusion in the laser therapy treated animal (middle). Good immediate perfusion is associated with good flap survival.



Fig 25:
Same experiment as in Figure 24. Transilluminated excised skin of the control (left) and laser treated animals (right) reveals better neovascularization in the latter compared with the former. There was no difference between the LED and control animals.

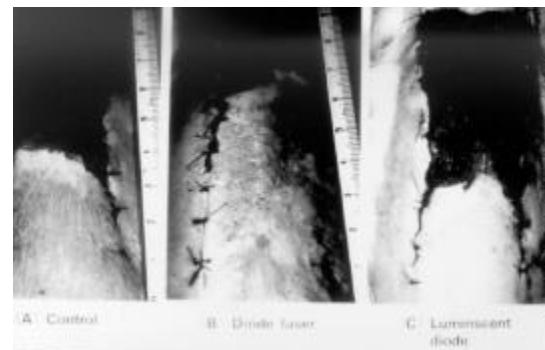


Fig 26:
Same experiment as Figures 24 and 25. The survival length compared for control (left), laser-treated (centre) and LED (right) treated animals. There was no significant difference between the unirradiated control and the LED-irradiated animals, but there was a statistically significant difference between the laser treat groups and both the former.

burns, ileus and flatus, cancer pain and so on. A very large body of data exists showing that LLLT at various wavelengths has important effects on all three stages of wound healing. LLLT accelerates and controls the very necessary inflammatory stage while at the same time activating platelets, mast cells and polymorphonuclear leukocytes all of which attract other cells into the wound or encourage differentiation from pericytic stem cells into activated fibroblasts, hemopoietic stem cells into endotheliocytes and monocytes into macrophages. (41) In addition to emitting chemotactic factors for other cells, activated platelets and leukocytes release a large variety of essential growth factors for the second stage fibroblasts and endothelial (42) activated leukocytes move to their prey, engulf and internalize then faster, (43) and mast cells degranulate faster. (44,45) At the transition from the inflammatory to the proliferative stage, the activated fibroblasts, endothelial cells and macrophage cells find a conducive environment to promote growth and synthesis, while activated macrophages continue to release greater quantities of fibroblast growth factor, (42), so that neocollagenesis, neoelastinogenesis, reepithelization and neovascularization occur more efficiently within a better and more ordered matrix. (46) Remodeling, the third phase is also affected by LLLT, with better oriented collagen fibres exerting more controlled contraction through increased fibroblast to myofibroblast transformation. (47)

As for postoperative pain, even with surgical lasers, patients reported lower postop pain compared with conventional scalpel or other surgical modality, particularly with the CO2 laser. Moore et al. presented a controlled study which showed that LLLT delivered immediately after major abdominal surgery resulted in less pain in the LLLT-treated patients, and also caused less demand for analgesics, nearly two-third less than of the untreated patients. (48)

One fast-growing subset of surgery is cosmetic surgery, and here the new laser classification I mentioned above is of greater importance than in other areas. As in the latest minimally- or almost noninvasive procedures, the epidermis is left intact and a controlled amount of damage is delivered to the papillary and upper reticular dermis. In this damage lies the 'grey area' I mentioned previously. The cells are damaged, but below their survival threshold, and the vast majority of them will survive. However, there is some irreversible change to the tissue microarchitecture, if not irreversible damage, therefore this is not in the original definitions of HLLT or LLLT, the latter calling for no damage or visible change at all (photobioactivation), and the former for total irreversible damage (photodestruction). Thus a third category was called for to encompass the minor but important upper dermal changes seen after the new range

of cosmetic laser surgical indications, and so I introduced medium reactive level laser treatment, MLLT, as shown schematically in Figure 11.

In my classification of cosmetic surgery in the realm of MLLT, I have introduced the idea of cosmetic medical soiree or care, which I denote as 'CoMeS'. When used in the skin, this is termed S-CoMeS, and for the whole body as B-CoMeS. Under both I have 'La Jeunesse', which is what I termed rejuvenation before that term actually appeared, and mild epilation, which is selective, non-permanent and not totally perfect. The definition of 'permanent' hair removal differs between the US and Japan, and my terminology is more akin to the US idea. Total and permanent hair removal is undesirable, as it will leave skin lacking the pilosebaceous units among whose main functions is keeping the skin supple and moist. Under my mild epilation, accomplished with MLLT, I aim to replace coarse, dark hair with much finer, fairer hair, so that the cosmetic appearance is one of hair removal even though very fine, light hair remains. I am preparing some articles which will examine the above concepts in depth, both clinically and experimentally, and which will appear in the near future.

Conclusions

Just as Medicine itself has adapted and changed to encompass new modalities such as the laser, so the use of the laser too must adapt and change. If I were asked to define the most vital point, it would be to exhort us all to remember that the patient is the most important reference point for us as clinicians taken together with the desired clinical result, and not the tool with which we achieve it. From my experience in treating over 45,000 patients with laser surgery, laser therapy, conventional methodology, MLLT or a combination of these I have evolved a patient-dependant Total Treatment Concept, (49) examined in detail elsewhere. This basically makes my staff and me take each patient as an individual and not to try to apply an indiscriminate and inflexible 'cookbook' approach, whether they are attending my clinics for removal of an extensive or minor nevus, scar revision, side effect control, hypertension, pain control or cosmetic surgery. A patient is no less a patient for wanting to look better or younger than they are, so I truly believe we must look seriously at cosmetic surgery with the same degree of scientific backing as we have laser therapy. As for laser therapy, as this Millennium Edition of the journal will surely show, it is no longer a second-rate quasi-science, wrapped in mystery and mumbo-jumbo, as the late Leon Goldman once referred to it. Once he saw the serious scientific intent behind what we were doing, during a presentation by one of my group at an ASLMS meeting he said; "Far from laughing at you, the Goldman family thanks you!" Healthy scepticism is an

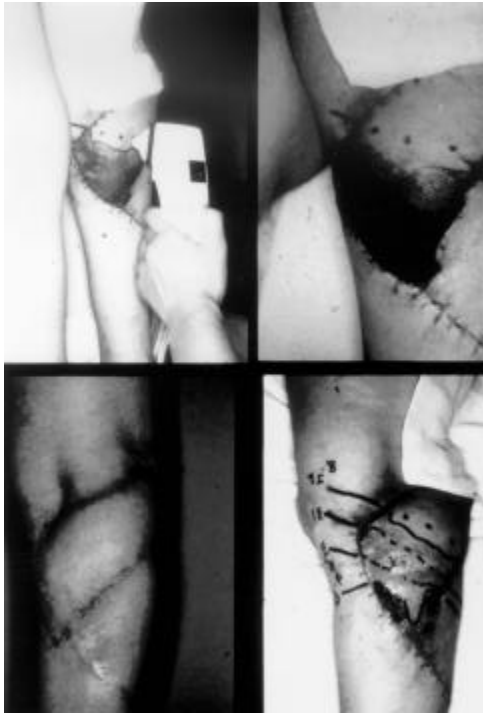


Fig 27:
LLLT for a failing flap. Necrosis is seen in a flap in the upper left. Left alone, this flap would have mostly failed. Laser therapy with the GaAlAs diode was started (upper right) and the progress of the recovery of the flap can be seen from the points recorded on it, with the final result with a healthy flap and good take seen in the lower right of the figure. (Figure courtesy of Prof Yu Maruyama)

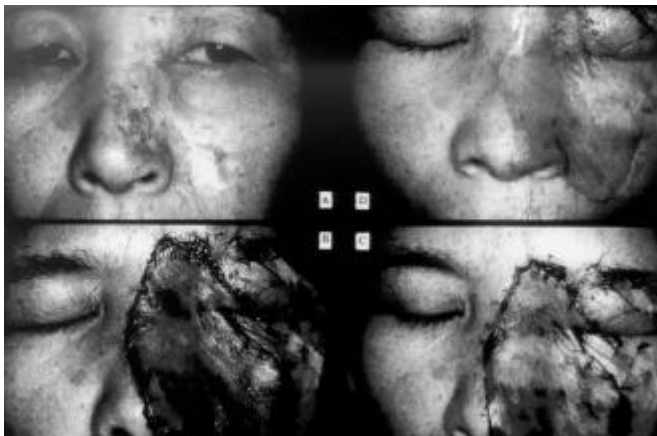


Fig 28:
LLLT for a compromised skin graft. A skin graft was applied after surgical removal of a skin cancer (upper left and right) but 4 days after removal of the dressing severe hematomas were compromising the 'take' of the graft (lower left). LLLT was applied giving the result as seen in the lower right frame, with full survival of an otherwise compromised graft. (Figure courtesy of Dr T Kioizumi)

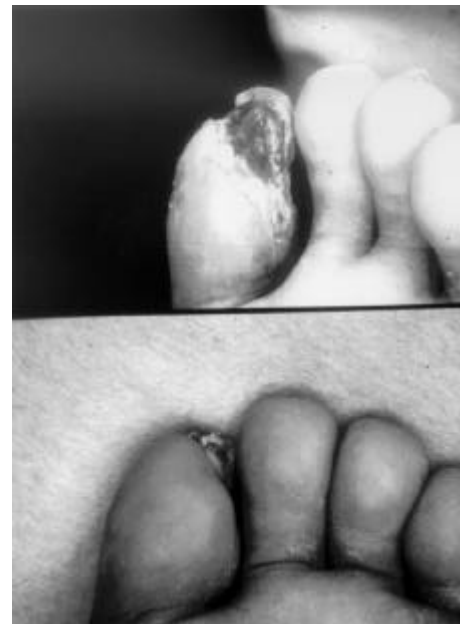

Fig 29:
LLLT for Buerger's Disease. The figure shows the typical ulcerous destruction of the big toe in an early stage Buerger's patient before (upper) and (lower) 15 months after 830 nm diode laser therapy. The extreme pain associated with this often fatal condition was also completely removed.

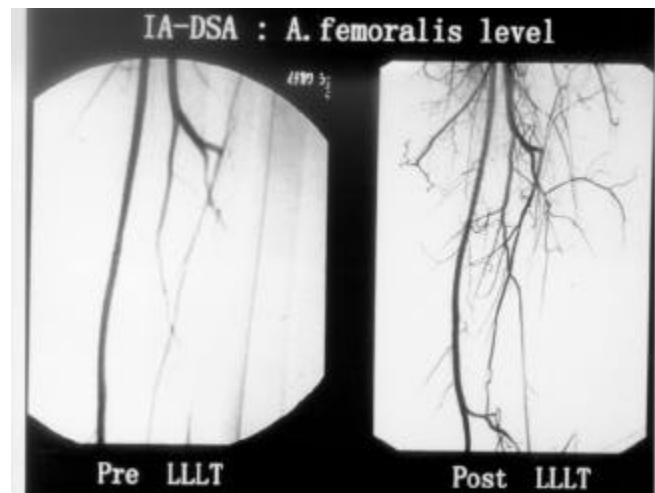


Fig 30:
Angiographic findings in the same patient as in Figure 29, taken at the level of the femoral artery before (left) and (right) after LLLT. The improvement in the vascular supply is clear, and in particular the neovascular supply should be noted.



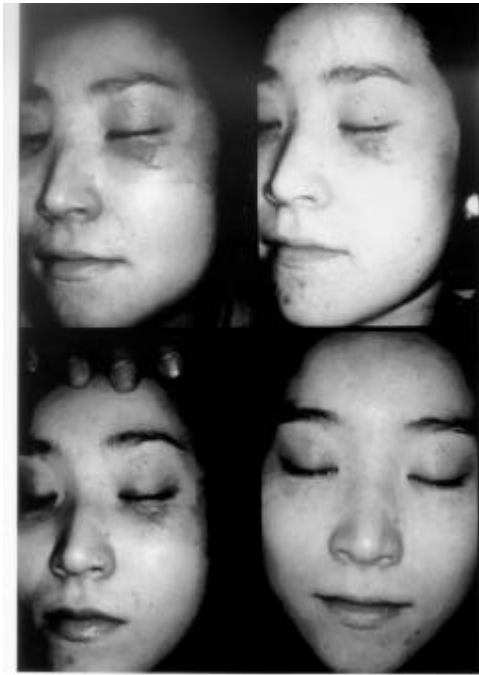

Fig 31:

Laser therapy in side-effect control. This female patient was unable to use antibiotics prescribed following an HLLT session for naevus of Ohta, and she developed bilateral ulceration in the infraorbital area. I first used defocused Nd:YAG therapy, but it had only fair results. Following application with the GaAlAs diode laser, the results were excellent.

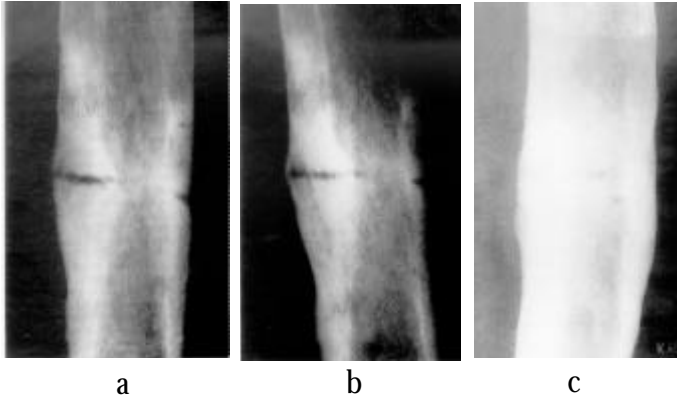
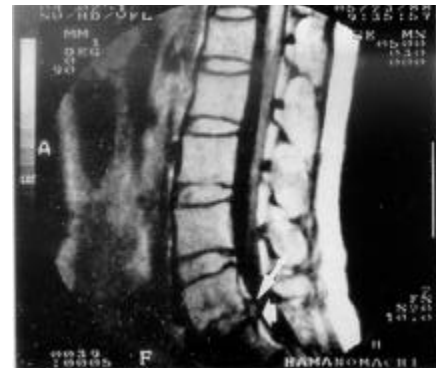

Fig 32:

Laser therapy for delayed union fracture in a 72 y.o. female patient with osteomyelitis. (a): The figure shows the radiographic finding at admission with a fracture of the left femur. (b): The radiographic findings 13 weeks after the first LLLT session. Fusion is occurring, with some increase in the radio-opacity of the cortical bone. (c): Radiographic findings at 26 weeks after initial consultation, with good radio-opaque callus and good closing of the remaining defect. (Figures courtesy of Dr T Abe)

a



b

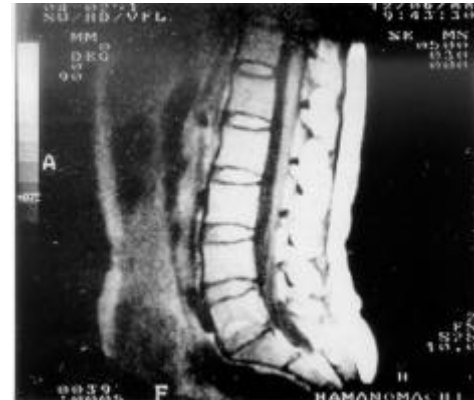

Fig 33:

LLLTL for herniated lumbar/sacral disc. (a:) MRI findings before LLLT reveal a herniation of the L5/S1 disc, with the extruded annulus extending into the spinal canal (arrow). (b:) MRI findings 7 months after the first LLLT session. A normal-appearing L5/S1 disc is seen, and the patient's ROM continued to improve.

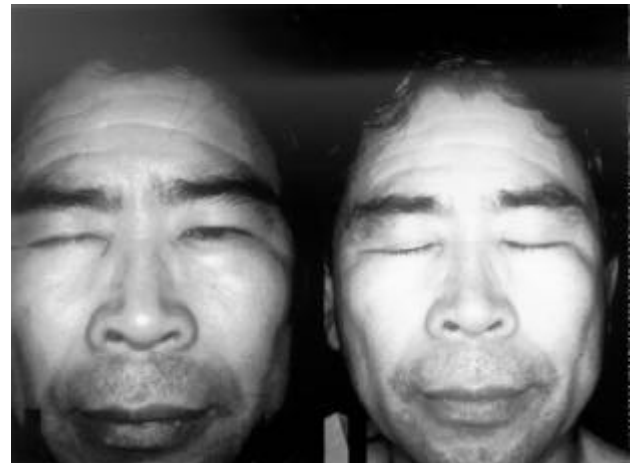

Fig 34:

LLLTL for facial palsy. This and the subsequent figure show the effectiveness of LLLT in a male patient with facial palsy of the left side of his face. (Left), before LLLT he was unable to close his left eye completely, and after LLLT (right) he could.

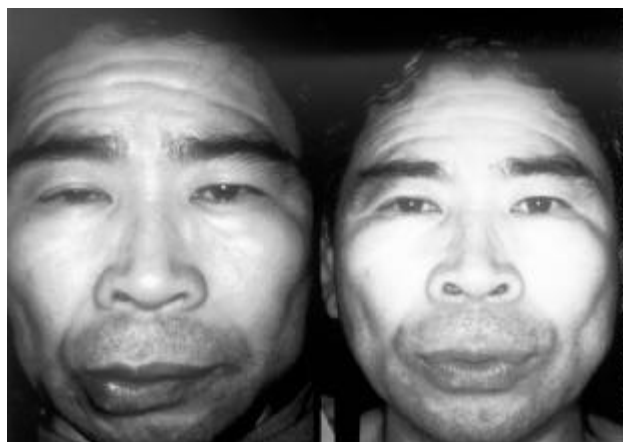

Fig 35:
(Same patient as in Figure 34). (Left) Typical pattern on attempting to raise the eyebrows reveal lack of response on the left side of the face. (Right) After LLLT, normal symmetry of the brow wrinkle pattern is seen, indicating removal of the palsy.

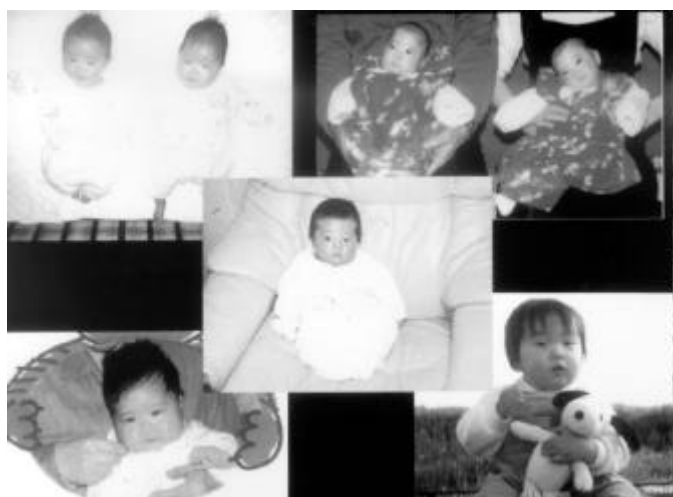

Fig 36:
LLLT for female infertility. A selection of the successful 'laser babies' delivered of supposedly 'poor responder' chronically infertile women following GaAlAs diode laser therapy.



excellent prod to force us to amass and examine scientific data carefully. At the end, we must remember tht it is our patients who are our ultimate judges. As we go into the New Millennium, I can clearly see that the future of LLLT

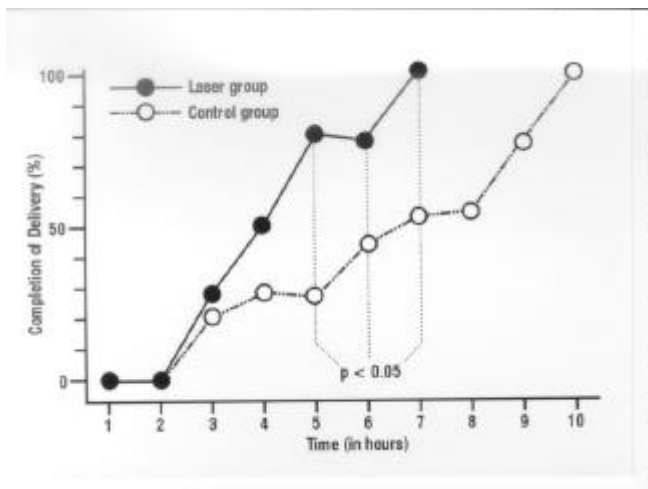


Fig 37:
Labor periods compared for laser therapy and control unirradiated groups. The laser therapy group exhibited statistically significantly faster delivery times than the control group.



Fig 38:
The Nobel laureate, Professor Arthur Schawlow, receiving laser therapy for hypertension from the author during the 1990 meeting of the International Laser Therapy Association in Okinawa, Japan. Please see the text for details of the efficacy of the treatment.

References

- 1: Bernstein I and Makoto S (1980): Biochemistry of Normal and Abnormal Epidermal Differentiation. University of Tokyo Press, Tokyo.
- 2: Ohshiro T and Calderhead RG. Low Level Laser Therapy, A Practical Introduction. John Wiley & Sons, Chichester UK, 1988.
- 3: Ohshiro T (1996): The laser apple: a new graphic representation of medical laser applications. *Laser Therapy*, 8: 185-190.
- 4: Heiwig EB et al. (1965): Anatomical and histochemical changes in skin after laser irradiation. *Fed Am Soc Exp Bio, Fed Suppl*, 24: 5483.
- 5: Moore KC, Hira N, Kumar PS, Jayakumar CS, and Ohshiro T (1988): A double blind crossover trial of low level laser therapy in the treatment of postherpetic neuralgia. *Laser Therapy, Pilot Issue*: 7-10.
- 6: Ohshiro T, and Shirono Y (1992): Retroactive study in 524 patients on the application of the 830 nm GaAlAs diode laser in low reactive level laser therapy (LLLT) for lumbago. *Laser Therapy*, 4: 121-126.
- 7: Ohshiro T: Case Reports. In (Ohshiro T Ed) *Low Reactive level Laser Therapy, Practical Application*. John Wiley & Sons, Chichester, UK, 1991. 113-118.
- 8: Amoils S, and Kues J (1991): The effect of low level laser therapy on acute headache syndromes. *Laser Therapy*, 3: 155-158.
- 9: Moore K: Neck Sprains. In (Ohshiro T Ed) *Low Reactive level Laser Therapy, Practical Application*. John Wiley & Sons, Chichester, UK, 1991. 109-112.
- 10: Shiroto C, Yodono M, and Nakaji S (1998): Pain attenuation with laser therapy: a retrospective study of the long-term LLLT experience in the private clinic environment. *Laser Therapy*, 10: 33-39.
- 11: Ohshiro T: Case Reports. In (Ohshiro T Ed) *Low Reactive level Laser Therapy, Practical Application*. John Wiley & Sons, Chichester, UK, 1991. 131,150.
- 12: Calderhead RG and Ohshiro T. The Nd:YAG and GaAlAs lasers: a laser comparative analysis in pain therapy. In (Atsumi K & Nimsakul N Eds) *Laser Tokyo '81*. Japan Society for Laser Medicine, 1982. 21:1.
- 13: Kemmotsu O, Sato K, Furumido H, Harada K, Takigawa C, Kaseno S, Yokota S, Hanaoka Y, and Yamamura T (1991): Efficacy of low reactive level laser therapy for pain attenuation of postherpetic neuralgia. *Laser Therapy*, 3: 71-76.
- 14: McKibbin LS, and Downie R (1991): LLLT in Canada. *Laser Therapy*, 3: 45-48.
- 15: Ohshiro T: The Mother Computer. In (Ohshiro T Ed) *Low Reactive level Laser Therapy, Practical Application*. John Wiley & Sons, Chichester, UK, 1991. 23-26.
- 16: Asagai Y, Ueno R, Miura Y, and Ohshiro T (1995): Application of low reactive level laser therapy (LLLT) in patients with cerebral palsy of the adult tension athetosis type. *Laser Therapy*, 7: 113-118.
- 17: Ohshiro T, and Maeda T (1992): application of 830 nm diode laser LLLT as successful adjunctive therapy of hypertrophic scars and keloids. *Laser Therapy*, 4: 155-168.
- 18: Fujino T: Plastic and reconstructive surgical aspects of low reactive level laser therapy (LLLT). In (Ohshiro T and Calderhead RG Eds.) *Progress in Laser Therapy*. John Wiley and Sons, Ltd, Chichester UK, 1991. 143-149.
- 19: Kubota J (1998): Treatment of skin ulcers with 830 nm GaAlAs diode laser therapy. *Laser Therapy*, 10: 123-128.
- 20: Sasaki K, and Ohshiro T (1989): Role of low reactive level laser therapy (LLLT) in the treatment of acquired and cicatricial vitiligo. *Laser Therapy*, 1: 141-146.
- 21: Ohshiro T, and Chin I (1992): low reactive level 830 nm diode laser therapy (LLLT) successfully accelerates regression of strawberry hemangioma in the infant: case reports. *Laser Therapy*, 4: 127-132.
- 22: Kubota J, and Ohshiro T (1989): The Effects of Diode Laser Low Reactive level Laser Therapy (LLLT) on Flap Survival in a Rat Model. *Laser Therapy*, 1: 127-135.
- 23: Kubota J, and Ohshiro T (1996): The effects of diode laser LLLT on flap survival: measurement of flap microcirculation with laser speckle flowmetry. *Laser Therapy*, 8: 241-246.
- 24: Kubota J (2001): Effects of Diode Laser Therapy on blood flow in axial pattern flaps in the rat model. *Lasers in Medical Science*, In Press.
- 25: Kioizumi T (1988): Low level diode laser treatment for hematomas under grafted skin and its photobiological mechanisms. *Keio Journal of Medicine*, 35: 28-35.
- 26: Schindl L, Dainz A, and Kern H (1992): Effect of low level laser irradiation on indolent ulcers caused by Buerger's disease; literature review and preliminary report. *Laser Therapy*, 4: 25-32.
- 27: Trelles MA and mayayo E (1987): Bone fractures consolidate faster with low power lasers. *Lasers in Surgery and Medicine*, 7: 36-45.
- 28: Asanami S, Shiba H, Ohtaishi M, Okada Y, Ohshaka F, and Tanaka Y (1993): The activatory effect of low incident energy hene laser irradiation on hydroxyapatite implants in rabbit mandibular bone. *Laser Therapy*, 5: 29-32.
- 29: Glinkowski W, (1990): Delayed union healing with diode laser therapy (LLLT). Case report and review of literature. *Laser Therapy*, 2: 107-110.
- 30: Abe T (1990): Diode laser LLLT-enhanced bone fusion of femoral shaft fracture complicated by chron-

- ic osteomyelitis: a case report. *Laser Therapy*, 2: 175-178.
- 31: Abe T, (1989): LLLT using a diode laser in successful treatment of a herniated lumbar/sacral disc, with magnetic resonance imaging (MRI) assessment: a case report. *Laser Therapy*, 1: 93-96.
 - 32: Asada K, Yutani Y, and Shimazu A (1989): Diode laser therapy for rheumatoid arthritis: a clinical evaluation of 102 joints treated with low reactive level laser therapy (LLLTT). *Laser Therapy*, 1: 147-152.
 - 33: Asada K, Yutani Y, Sakawa A, and Shimazu A (1991): Clinical application of GaAlAs 830 nm diode laser in treatment of rheumatoid arthritis. *Laser Therapy*, 3: 77-82.
 - 34: Khullar SM, Brodin PB, Barkvoll P, and Haannes HR (1996): Preliminary study of low-lwvwl laser treatment of long-standing sensory aberrations in the inferior alveolar nerve. *Journal of Oral and Maxillofacial Surgery*, 54: 2-7.
 - 35: Midamba ED, and Haanaes HR (1993): Effect of low level laser therapy (LLLTT) on inferior alveolar, mental and lingual nerves after traumatic injury in 15 patients. a pilot study. *Laser Therapy*, 5: 89-94.
 - 36: Terashima Y: Clinical application of LLLTT in the field of obstetrics and gynaecology. In (Ohshiro T and Calderhead RG Eds.) *Progress in Laser Therapy*. John Wiley and Sons, Ltd, Chichester UK, 1991. 191-196.
 - 37: Mazo V (1994): Transrectal low level laser therapy in the management of prostatic problems: a pilot study. *Laser Therapy*, 6: 209-214.
 - 38: Umeda T, (1990): Blood pressure controlled by low reactive level diode laser therapy (LLLTT). *Laser Therapy*, 2: 59-64.
 - 39: Yamazaki J and Morishita T. Blood pressure control with diode LLLTT. In (Ohshiro T and Calderhead RG Eds.) *Progress in Laser Therapy*. John Wiley and Sons, Ltd, Chichester UK, 1991. 138-142.
 - 40: He J-Z (1991): Clinical Observation in 500 Cases of Diarrhoea in Children Treated with Two helium-Neon Laser 'Light Needles'. *Laser Therapy*, 3: 93-98.
 - 41: Dyson M: Cellular and subcellular aspects of low level laser therapy. In (Ohshiro T and Calderhead RG Eds.) *Progress in Laser Therapy*. John Wiley and Sons, Ltd, Chichester UK, 1991. (Ohshiro T and Calderhead RG Eds.) *Progress in Laser Therapy*. John Wiley and Sons, Ltd, Chichester UK, 1991. 221-224.
 - 42: Bolton P, Dyson M, and Young S (1992): The effect of polarized light on the release of growth factors from the U-973 macrophage-like cell line. *Laser Therapy*, 4: 33-38.
 - 43: Osanai T, Shiroto C, Mikami Y, Kudou e, Komatsu T, Suzuki K, Nakaji S, Kumae T, Sugawara K, and Sasake M (1990): Measurement of GaAlAs diode laser action on phagocytic activity of human neutrophils as a possible therapeutic dosimetry determinant. *Laser Therapy*, 2: 123-134.
 - 44: Yurt RW: Role of mast cells in trauma. In (Dineen B. Hildick-Smith G eds.): *The Surgical Wound*. Philadelphia, Lea & Febiger, 1981. pp. 37-62.
 - 45: El Sayed, S. and Dyson, M. (1990). A comparison of the effects of multiwavelength light produced by a cluster of semiconductor diodes and of each individual diode on mast cell number and degranulation in intact and injured skin. *Lasers in Surgery and Medicine*, 10: 559-568.
 - 46: Williams PL, Warwick R, Dyson M, and Bannister LH (1989). *Gray's Anatomy*, 37th Edition. Edinburgh, Churchill Livingstone. pp. 84-89.
 - 47: Enwemeka CS, Cohen-Kornberg E, Duswalt EP, Weber DM, and Rodriguez IM (1994): Biomechanical effects of three different periods of GaAs laser photostimulation on tenotomized tendons. *Laser Therapy*, 6: 181-188.
 - 48: Moore KC, Hira N, Broome IF, and Cruikshank JA (1992): The effect of infra-red diode laser irradiation on the duration and severity of postoperative pain: a double blind trial. *Laser Therapy*, 4: 145-150.
 - 49: Ohshiro T: Total treatment concept (TTC). In (Ohshiro T, Ed) *Laser Treatment for Naeivi*. John Wiley and Sons, Ltd, Chichester, UK, 1995. 211-214.

